



DENGUE FEVER MASQUERADING AS ACUTE APPENDICITIS: A DIAGNOSTIC CHALLENGE

Dr. Wajeeh Naveed^{1a}, Dr. Verisha Mansoor^{1b}, Dr. Rafia Khalid²

¹Department of Internal Medicine, OMI Hospital, Karachi, Pakistan ²Aziz

Medical Center, Islamabad, Pakistan

ARTICLE INFO	ABSTRACT
<p>Keywords</p> <p>Acute Abdomen, Imaging, Serology, Endemic Areas, Unnecessary Surgery, Case Report</p> <p>Corresponding Author:</p> <p>Dr. Wajeeh Naveed</p> <p>Department of Internal Medicine, OMI Hospital, Karachi, Pakistan.</p> <p>Email: wajeehnaveed@yahoo.com</p>	<p>Dengue fever can rarely mimic acute appendicitis, posing a diagnostic challenge. We report a case of a 16-year-old with right iliac fossa pain initially suggestive of appendicitis, later diagnosed as dengue fever. Timely recognition through imaging and serology prevented unnecessary surgery. Clinicians should consider dengue in differential diagnoses of acute abdomen in endemic areas.</p>

INTRODUCTION

Dengue fever is an acute febrile disease that is arthropod borne. It presents as a fever with retroorbital pain, severe body ache, nausea, anorexia, vomiting and blanching rash. It is prevalent more in the tropical regions. In Pakistan the first case was reported in 1994 and Pakistan experienced an outbreak of dengue fever in 2005, between 2015-2019 there were a reported 90,400 cases of this febrile illness with 169 fatalities. [1] The fever is caused by two species of a mosquito namely *Aedes aegypti* and *Aedes albopictus*. [2] dengue fever can present from sub-

clinical infection to dengue hemorrhagic fever or dengue shock syndrome involving third spacing with associated pleuro-peritoneal serositis [3].

There have been reports of unusual manifestation of dengue fever with pancreatitis, acalculous cholecystitis, myocarditis, and acute appendicitis.

Prompt identification of clinical features of appendicitis secondary to dengue fever can prevent from the mortality from non-therapeutic Appendectomies.

CASE PRESENTATION

A 16-year-old child with no prior history of any co-morbidities presented to the emergency department of OMI hospital in Karachi, with complaints of fever, pain in abdomen, anorexia, nausea and vomiting all these symptoms have been happening for 3 days. The pain in the abdomen was localized to the right iliac fossa and was associated with nausea and vomiting. There was no association of the fever with a petechial rash. On physical examination there was fever of 38.6 C and a pulse rate of 100 beats per minutes. In the abdomen there was marked tenderness in the right iliac fossa as well as rebound tenderness. Complete blood picture showed heme concentration with a H.B of 18.3g/dl and a hematocrit of 55% there was also severe thrombocytopenia with platelet count of $35 \times 10^9/L$, The surgical team was consulted and they ordered an ultra-sound whole abdomen which showed partially compressible fluid filled aperistaltic structure in right iliac fossa to further confirm the diagnosis a CT-scan whole abdomen with contrast was requested. The patient was admitted into the intensive care unit for monitoring purpose for 48 hours. The CT-scan of the abdomen showed Mid part of the appendix along the right psoas muscle which appeared slightly distended measuring 1.0 cm in AP diameter, the wall appeared slightly indistinct at this level, however the visualized portion is measuring 0.3 cm. Findings were associated with surrounding fat strandings and fluid collection. Few lymph nodes were also enlarged around the anterior part of inferior vena cava, all these findings were highly suspicious of acute appendicitis as a result the diagnosis was made as acute appendicitis based on the clinical picture and the radiological findings. The patient experienced a worsening of the right iliac fossa pain the lab markers repeated the next day showed $38 \times 10^9/L$ and the H.B was 12.7g/dl. The dengue NS-1 antigen came out positive along with dengue IgM serology, the diagnosis of appendicitis secondary to dengue fever was made and the patient was made NPO and was started on ceftriaxone and metronidazole. The patient's condition stabilized as a result

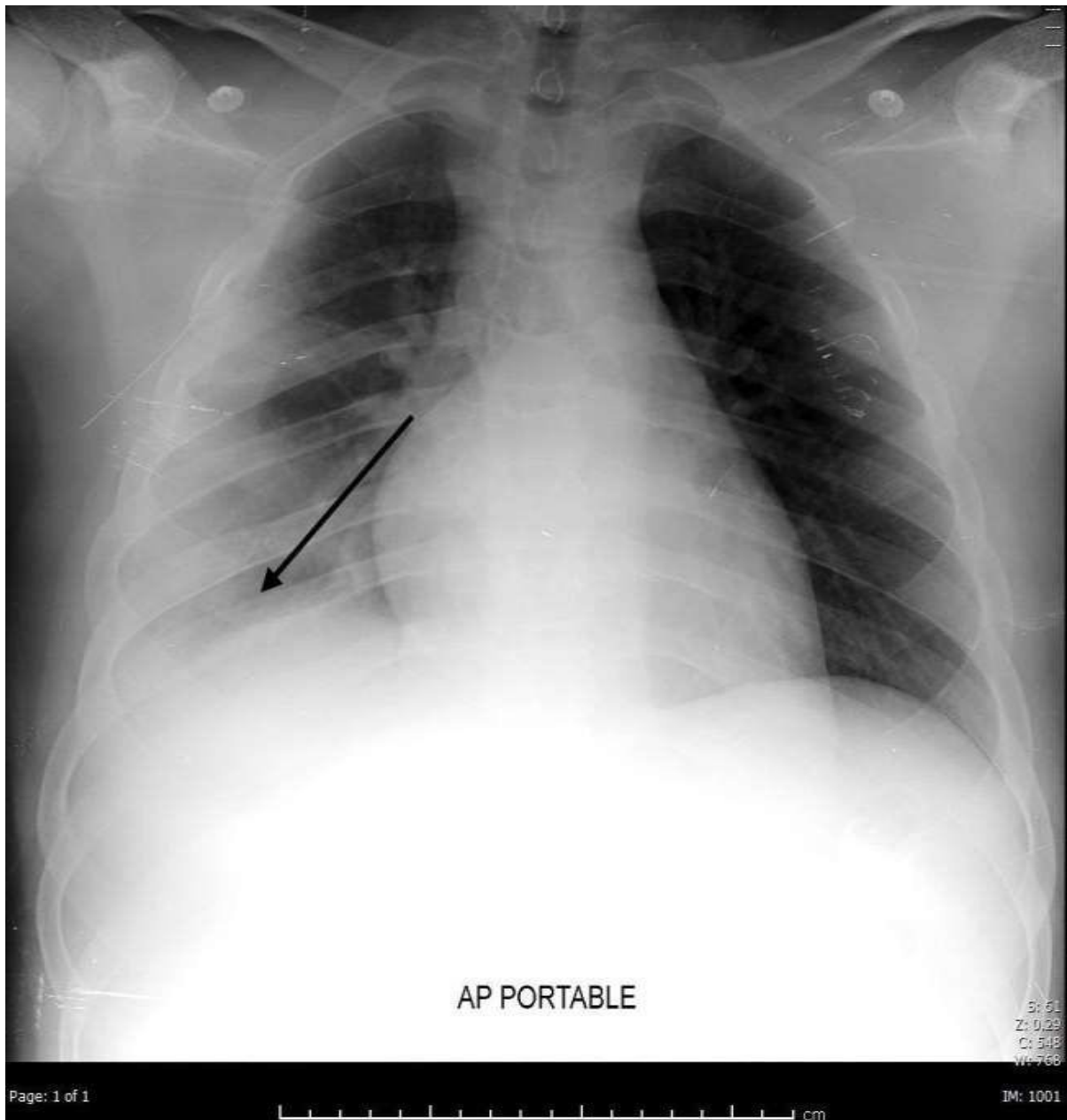
the patient was stepped down to the ward and was discharged on oral medications including the anti-biotics to be continued for 5 days.

The repeat blood tests were done which had normalized.

ward and was discharged on oral medications including the anti-biotics to be continued for 5 days.

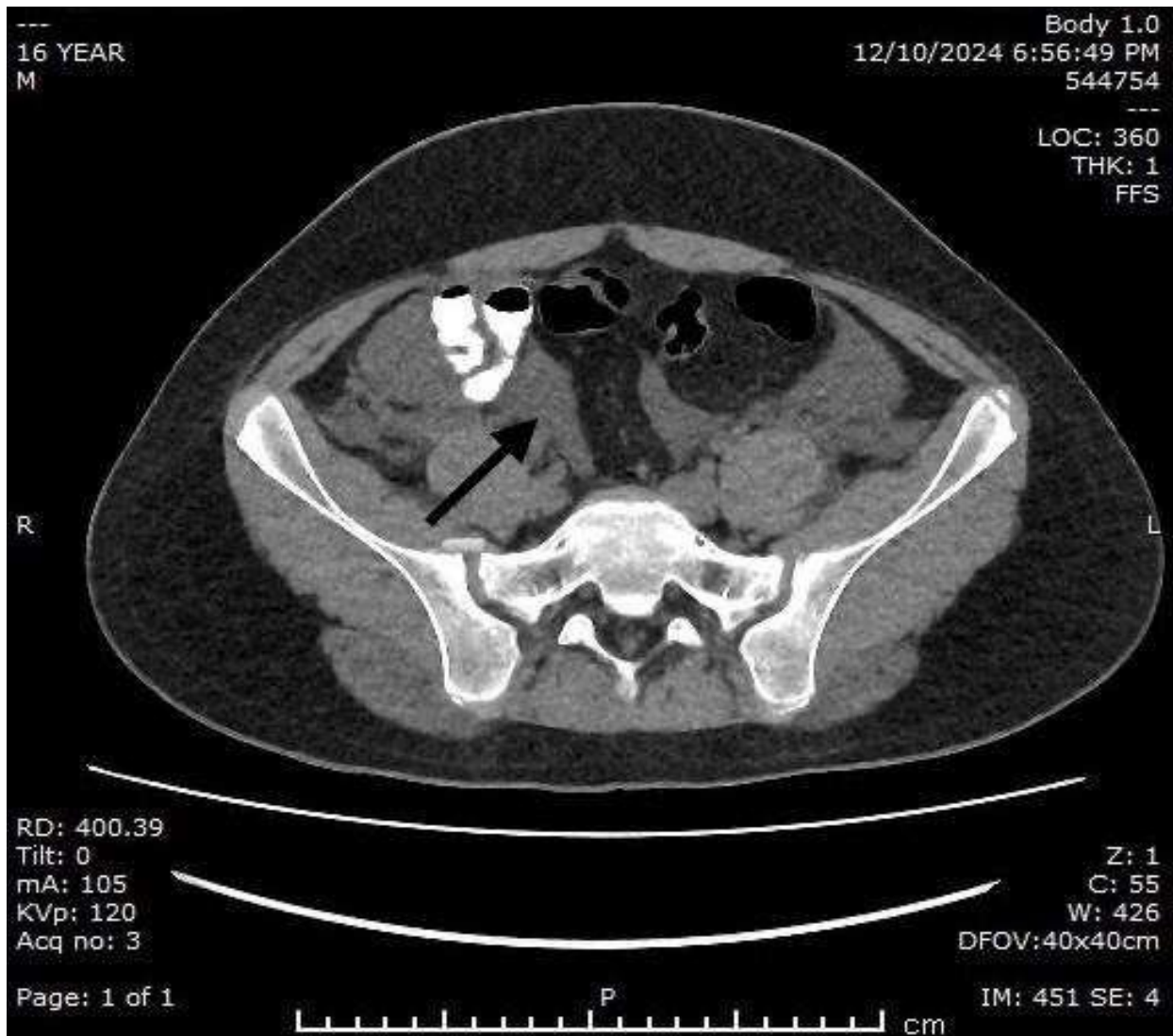
The repeat blood tests were done which had normalized.

Fig. 1



Chest X-ray showing evidence of fluid in the pleural space secondary to dengue serositis

Figure: 2



CT-scan with contrast of the patient showing enlarged lymph nodes throughout the mesentery along with swollen appendix.

DISCUSSION

Dengue fever causes mostly asymptomatic or mild disease among people residing in tropical areas the incidence of this febrile illness mostly increases during the rainy season. The disease has a varied presentation it is an infection transmitted by the bite of a female arthropod, particularly the *Aedes aegypti* or *Aedes albopictus*, which has been infected by one of the four dengue virus (DENV) serotypes: DENV-1, DENV-2, DENV-3, or DENV-4. An additional fifth serotype of the virus has recently been described. This disease is endemic to tropical and subtropical regions around the world, especially in urban and suburban regions, and represents an important public health problem [4]. When the *Aedes aegypti* mosquito bites a person infected by DENV, the virus

replicates in the intestines of the mosquito before disseminating to its secondary tissues, including the salivary glands. The time between entry of the virus and transmission to a new host is called *extrinsic incubation*, and when the temperature is between 25°C and 28°C, this period lasts between eight to twelve days. The Aedes mosquito has adapted to be able to reproduce in manmade structures including buckets, clay pots, discarded containers, used tires, stormwater drains, and more; this has rendered dengue an insidious disease in densely populated urban centers [5]. A study was carried out according to which There were 17 cases (7 males, Age range 10–71 years), with a presumptive diagnosis of an acute abdomen fulfilling the inclusion criteria of the study. Twelve patients were initially admitted to the surgical unit as evaluated by the referring general practitioner or the hospital accident and emergency admitting officer. Other 5 cases were admissions to medical units due to abdominal pain and fever referred to the surgeons by the physicians after their initial assessment with suspicion of acute appendicitis (2 cases), acute cholecystitis (2 cases) and acute pancreatitis (1 case) [6]. This case was a rare presentation of dengue fever along with acute abdomen. In another study an analysis of 357 dengue fever patients found that 276 of them had nonspecific abdominal pain without obvious abdominal symptoms, 43 (12.04%) had acute abdominal pain with clear abdominal symptoms, and only 38 (10.64%) did not have any abdominal pain at all [7].

However acute abdomen in dengue has no definitive cause, the enlarged lymph nodes and fluid in the right iliac fossa coupled together secondary to third spacing which is characteristic of dengue might be a plausible explanation [8].

Prior writers who have handled Dengue fever mimicking Acute appendicitis cases have discussed the importance of early disease differentiation to prevent needless surgical procedures.

CONCLUSION

Dengue fever is a common arboviral disease with a wide spectrum of clinical manifestations, including rare presentations such as acute appendicitis. This case highlights the importance of recognizing dengue fever as a potential cause of acute abdomen, particularly in endemic regions. Given the risk of unnecessary surgical interventions, clinicians must maintain a high index of suspicion for atypical presentations of dengue fever and utilize imaging and laboratory findings to guide management. Early recognition and appropriate medical management can prevent complications and improve patient outcomes. This case underscores the need for further research

into the pathophysiology of dengue-associated acute abdomen to refine diagnostic and treatment strategies.

REFERENCES

1. Mushtaq, S., Abro, M. T., & Hussain, H. U. (2024). Dengue cases presenting to the emergency department of a tertiary care hospital in late 2021: a Cross-Sectional Study in Karachi. *International Journal of Public Health*, 69. <https://doi.org/10.3389/ijph.2024.1606753>
2. Mcfarlane, M., Plummer, J., Leake, P., Powell, L., Chand, V., Chung, S., & Tulloch, K. (2013). Dengue fever mimicking acute appendicitis: A case report. *International Journal of Surgery Case Reports*, 4(11), 1032–1034. <https://doi.org/10.1016/j.ijscr.2013.08.017>
3. Thadchanamoorthy, V., Ganeshrajah, A., Dayasiri, K., & Jayasekara, N. P. (2022). Acute appendicitis during the recovery phase of dengue hemorrhagic fever: two case reports. *Journal of Medical Case Reports*, 16(1). <https://doi.org/10.1186/s13256-022-03443-2>
4. Cristodulo, R., Luoma-Overstreet, G., Leite, F., Vaca, M., Navia, M., Durán, G., Molina, F., Zonneveld, B., Perrone, S. V., Barbagelata, A., & Kaplinsky, E. (2023). Dengue myocarditis: a case report and major review. *Global Heart*, 18(1). <https://doi.org/10.5334/gh.1254>
5. Weerakoon, K. G., Kularatne, S. A., Edussuriya, D. H., Kodikara, S. K., Gunatilake, L. P., Pinto, V. G., Seneviratne, A. B., & Gunasena, S. (2011). Histopathological diagnosis of myocarditis in a dengue outbreak in Sri Lanka, 2009. *BMC Research Notes*, 4(1). <https://doi.org/10.1186/17560500-4-268>
6. Jayasundara, B., Perera, L., & De Silva, A. (2016). Dengue fever may mislead the surgeons when it presents as an acute abdomen. *Asian Pacific Journal of Tropical Medicine*, 10(1), 15–19. <https://doi.org/10.1016/j.apjtm.2016.12.010>
7. Shamim, M. (2010). Frequency, pattern and management of acute abdomen in dengue fever in Karachi, Pakistan. *Asian Journal of Surgery*, 33(3), 107–113. [https://doi.org/10.1016/s10159584\(10\)60019-x](https://doi.org/10.1016/s10159584(10)60019-x)
8. Gurung, S., Karki, S., Khadka, M., Gurung, S., & Dhakal, S. (2022). Acute acalculous cholecystitis in a patient with dengue fever: A case report. *Annals of Medicine and Surgery*, 84. <https://doi.org/10.1016/j.amsu.2022.104960>